



Study of Digestive Morphology, Osteology of *Osteobrama Vigorsii* (Sykes, 1839) from Nira River Bhor, Maharashtra

Nirbhay Sudhir Pimple^{1*}

¹Department of Zoology, Abasaheb Garware College, Pune, India.

ABSTRACT

There are significant differences in the construction and working of the alimentary system concerning species, habitat, and eating habits of any organism. Fish feed behavior is a major element responsible for their nourishment and development, alteration in the environmental opportunity such as eutrophication as well as anthropogenic activities affect fish species differently and also affect food availability. To understand the digestive system, Morphological studies in the digestive tract of fish were performed on *Osteobrama vigorsii* (Sykes, 1839). The average length of the alimentary canal is 27.57 cm. The relative intestinal index was calculated to be 1.20 ± 0.085 . The alimentary canal is separated into the following regions namely, the buccal cavity (mouth) followed by the orobranchial cavity which opens up into the esophagus. The esophagus opens up into the stomach which leads into the intestines and retained the anus. The intestine shows 5 folds coiled and connected with mesenteries. In this current study osteology of the buccal cavity revolved, that the upper jaw and lower jaw are toothless, as well as palatine teeth are absent. Although the lower jaw displays strong dentary, which at the distal end is broader while it appears tapering towards the proximal end. The lower jaw is devoid of teeth. The oropharyngeal cavity was almost triangular made of strainer gill and pharyngeal teeth apparatus. All gill arches indicate the absence of denticles. Ceratobranchial V indicates the presence of a six oval-shaped tooth plate located on the ventral side of the oropharyngeal cavity.

Keywords: Relative intestinal index, Palatine teeth, Osteology, Ceratobranchial

Corresponding author: Nirbhay Sudhir Pimple

e-mail ✉ nsp.agc@mespune.in

Received: 09 December 2020

Accepted: 28 March 2021

INTRODUCTION

The sound operation of organisms completely relies upon the type of nourishment the organism derives from the environment and its usage for its increase and well-being in any natural habitat. Feeding has a direct effect on the increased pattern and productiveness of fish, as consumption is the foremost pursuit in the life cycle of fish (Joadder, 2006; Hossain *et al.*, 2010; Manon & Hossain, 2011). The feeding ability of the fish additionally relies upon its physiological status, age, sex, and the physicochemical condition of the habitat. The feeding rate for carp varies depending on size, age of fish, water temperature, the relative quantity of natural food, and the quality of feed. Feeding depth has been suggested to be improved with the accessibility of the meals additives in the environments (Lawson & Aguda, 2010; Manoharan *et al.*, 2012).

The feeding demeanor of fish is the most valuable characteristic directly related to their nourishment, biological process (Joadder & Hossain, 2008). Changes in the environmental conditions include eutrophication, which uniquely impacts the fish species and additionally affects the availability of meals type (Al-Awady, 2013). To understand the mechanism of consumption of food, its digestion inside the stomach, and finally the absorption of meals. As

the fish gets bigger, larger sizes of food had been desired to smaller ones; hence, size of fish is related to feeding capacity (Khaing & Khaing, 2020). The morphological research at the digestive tract of fish is considered one of the handiest tools (Xiong *et al.*, 2011; Løkka *et al.*, 2013; de Melo Germano *et al.*, 2014). As per the model and availability of the food and the feeding habits, the digestive system of fishes suggests marked morphological as well as functional diversity (Murray *et al.*, 1996; Diaz *et al.*, 2003). The anatomy of the mouth and intestine and the aforementioned histology are changed to house the feeding behavior (Agbugui & Oniye, 2019). Compared with different vertebrates the intestine in fishes is an elongated tube starting from the mouth followed by the esophagus, stomach, gut, and end by rectum, at some point of the duration the diameter of the gut varies (Abaurrea-Equisoain & Ostos-Garrido, 1996; Agarwal, 1996; Albrecht *et al.*, 2001; Boćina *et al.*, 2017). In most fishes, the selection, seizing of the food, and pushing it lower back into the esophagus is completed by way of the oral and pre-oral hollow space (Rodrigues *et al.*, 2006; Wilson & Castro, 2010).

As in line with the species, precise variations inside the structural and anatomical structure endeavor are observed in the fishes (Albrecht *et al.*, 2001; Wilson & Castro, 2010; Xiong *et al.*, 2011). Carnivorous fish species are diagnosed to have brief gut, as a result the presence of unique organs to assist in digestion. The stomach is composed of numerous longitudinal folds, gastric glands, gastric pits, columnar striated epithelium, lamina propria, and

microvilli making the function of the stomach specialized (El-Naggar *et al.*, 2019). Understanding the anatomy, the digestive system of fish is the primary requisite in understanding the feeding behavior of the fish and could benefit the fishery control program (Abaurrea-Equisoain & Ostos-Garrido, 1996; de Melo Germano *et al.*, 2014; Santos *et al.*, 2015; Purshothaman *et al.*, 2016).

Present work deals with the Study Of Digestive Morphology, Osteology in *Osteobrama vigorsii* (Sykes, 1839) for the duration of the study period. The fish is commercially critical and are consumed through massive populace inside the country of Tamil Nadu, Andhra Pradesh, and Maharashtra, it becomes vital to apprehend the food and feeding sample of the fish from business and fishery technological know-how component. The significance of the work would be attributed to the direction of making plans and executing diverse strategies as a way to acquired maximum yield.

MATERIALS AND METHODS

Specimens of *Osteobrama vigorsii* (Sykes, 1839) (n = 30 had been collected in 2021 at Bhor from the nearby fish market 18°08'56.9"N 73°50'47.0"E Pune district Maharashtra, India. Specimens include a combined populace of females and males with std length (96.95 ± 3.15 mm), and weight (21.00 ± 1.04 g). The fishing techniques used by the fishermen for harvesting the fish mainly covered the variable mesh-sized nets specifically cast and gill net. The fishing gears had been laid overnight in the river and were retrieved the subsequent morning. Specimens accrued have been canned in 10% formalin and carried to the research center for additional analysis. Standard length (SL), total length (TL) was calculated for each representative of *Osteobrama vigorsii* (Sykes, 1839) to the nearest 0.1 mm the use of virtual caliper (Mitutoyo, Japan). The total weight (W) became decided to nearest 0.01 g by the usage of a digital weighing machine (Contech, India).

Relative gut analysis:

The relative intestine length was studied for *Osteobrama vigorsii* (Sykes, 1839) for a calendar year. Ergodic sampling was instituted, the intestine length (GL), preferred length (SD) was measured for the specimen accrued every month in cms. The relative gut indices for the fishes had been calculated by the usage of the formula:

$$\text{Relative gut Length (RGL)} = \frac{\text{gut length (GL)}}{\text{general body length (SL)}} \quad (1)$$

Osteology

A study of *Osteobrama vigorsii* (Sykes, 1839) was carried out to understand the relation between the layout of oral cavity structure. Specimen (n = 2) was cleaned then stained twice (C

and S) following protocol (Potthoff *et al.*, 1984). The photography of the entire fish and the buccal cavity was carried out by using Canon DSLR 600D.

RESULTS AND DISCUSSION

Gross morphology and anatomy studies

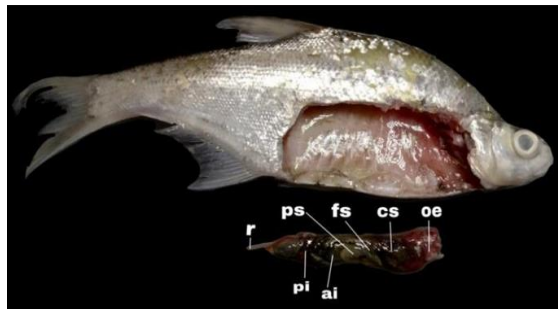
The specimen for the present study *Osteobrama vigorsii* (Sykes, 1839) consisted of a mixed population of males and females. The average general length for *Osteobrama vigorsii* (Sykes, 1839) was determined to be 76.08 ± 2.14 mm, and weight 40.34 ± 1.03 gms. The average length of the alimentary canal of *Osteobrama vigorsii* (Sykes, 1839) was calculated to be 27.57 cms (**Figure 1a**). The alimentary canal is separated into the buccal cavity i.e mouth which leads to the orobranchial cavity which opens up into the esophagus followed by the stomach. The stomach opens up into the intestine which ends up into the rectum which leads to the anus. The average length of mouth hollow space was (2.13cm), esophagus turned into (3.47cm), belly (4.67cm), intestine (anterior gut (7.87cm), posterior gut (9.43cm), and rectum (3.45cm).

In the case of *Osteobrama vigorsii* (Sykes, 1839) the mouth is superior, the lower jaw is sticking out. Both the jaws are devoid of the tooth in the fish beneath examination. The upper jaw suggests the absence of palatine teeth (**Figure 2**). The lower jaw shows a sturdy dentary which is broader at the distal quit while tapering towards the proximal give up, it shows the absence of teeth (**Figure 2**). The empty oropharyngeal space in fish becomes an extremely shaped triangle, made up of strainer gills and the material of its pharyngeal shell (**Figure 1**). The gill chamber is made up of five-gill arches (**Figure 2**). Gill arches namely I, II, III, IV, and V. all gill arches are composed of two parts, mainly ventral and dorsal. all gill arches indicate the absence of denticles. Ceratobranchial V indicates the presence of six oval-shaped plates that may be located on the ventral portion of the empty oropharyngeal space (**Figure 2**). The short muscular throat begins to drop at the distal end of the orobranchial cavity gradually enters the abdomen. Near the bilobed liver, the stomach is present. The stomach is separated into three regions which are cardiac, fundac, and pyloric (**Figures 1a and 2**). The cardiac stomach in *Osteobrama vigorsii* (Sykes, 1839) is short of the continuation of the esophagus, wherewith the help of the fundac abdomen it becomes slightly larger and forms a lump almost identical in shape. The pyloric area is small, an almost elevated area that connects the gut thru the pyloric sphincter. The intestines show 5 folded curves connected with mesenteries (**Figure 2**). The whole shape resembles a bolus (**Figure 1a**). Relative gut analysis: In the current work the average relative gut analysis associated with *Osteobrama vigorsii* (Sykes, 1839) was calculated at 1.2 ± 0.085 The result is presented in **Table 1**.

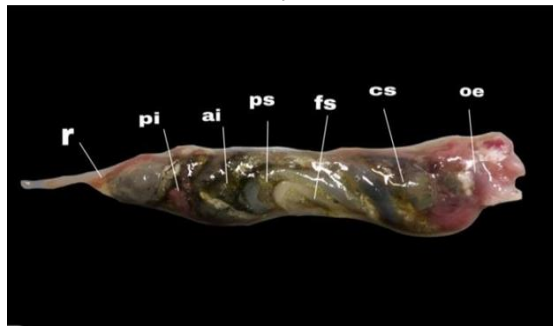
Table 1. Relative Gut Length of *Osteobrama vigorsii* (Sykes, 1839), from Nira River

Months	Average body length	Average gut length	Sample number	Average relative gut length	Standard deviation
APR	15.5	19.6	10	1.26	±0.085
MAY	37.7	51.9	15	1.3	±0.094
JUN	40.3	48.7	13	1	±0.065


JUL	32.5	39.3	14	1.2	±0.085
AUG	24.6	29.7	12	1.2	±0.085
SEP	20.21	24.4	11	1.2	±0.085
OCT	32.12	38.8	10	1.2	±0.085
NOV	34.21	41.3	9	1.21	±0.085
DEC	23.51	28.4	10	1.2	±0.085
JAN	34.11	41.2	13	1.2	±0.085
FEB	18.43	22.3	14	1.2	±0.085
MAR	12.34	14.9	15	1.2	±0.085



a)



b)



c)

Figure 1. The alimentary canal of *Osteobrama vigorsii* (Sykes, 1839) from Nira River, Bhor, Maharashtra, India. a) The coiled intestine and the entire alimentary canal. b) The alimentary canal showing (oe) esophagus, (cs) cardiac stomach, (fs) fundus stomach, (ps) pyloric stomach, (ai) anterior intestine, (pi) posterior intestine, (r) rectum. c) The alimentary canal of *Osteobrama vigorsii* (Sykes, 1839) from Nira River, Bhor, Maharashtra, India

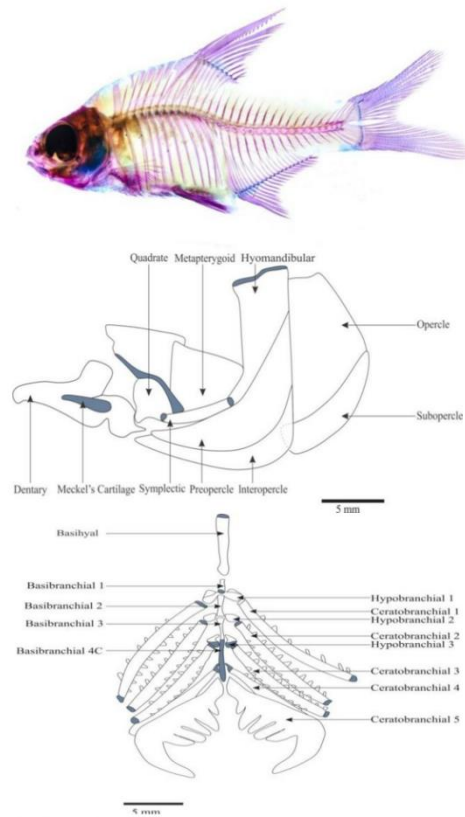


Figure 2. Osteology of *Osteobrama vigorsii* (Sykes, 1839) from Nira River, Bhor, Maharashtra, India

The morphology of fish 'alimentary canal is consistent with their dietary habits and adaptability that occurred during evolution (Albrecht *et al.*, 2001; Yashpal *et al.*, 2009; Nazlić *et al.*, 2014). In the present study of *Osteobrama vigorsii* (Sykes, 1839) the esophagus was short, the abdomen followed by intertwined intestines showing 5 rotations. The digestive tract is relatively long which is a common characteristic of omnivorous fish. The studies are consistent with studies conducted by (German *et al.*, 2010). The stomach is composed of numerous longitudinal folds, gastric glands, gastric pits, columnar striated epithelium, lamina propria, and microvilli making the function of the belly specialized (Alabssawy *et al.*, 2019; El-Naggar *et al.*,

2019). The relative intestinal index of *Osteobrama vigorsii* (Sykes, 1839) in the present study was 1.20 ± 0.085 , the relative intestinal index (RGI) was calculated to be 1.1 ± 0.080 . The (RGI) studies of (Xiong *et al.*, 2011; Garcia *et al.*, 2012; Santos *et al.*, 2015) show an association between RGI and fish species. The (RGI) index deviates from fish species and the development phase (German *et al.*, 2014). The (RGI) index is divided when it falls between (RGI = 0.6-0.8) and is considered omnivorous (RGI = 0.8-0.1) and herbivorous (RGI = 2.5-16.4) (German *et al.*, 2014) It intimate that *Osteobrama vigorsii* (Sykes, 1839) is omnivorous fish.

Digestive analysis shows the presence of insects, plant material, debris, and part of the soil in the intestines of fish. The size of the diet eaten by fish is often associated with sound structure and the sizing of the fish (Shukla & Patel, 2013; Dey *et al.*, 2015). In the case of *Osteobrama vigorsii* (Sykes, 1839) jaw is without teeth. Existing gill rakers work through a filter to hold part of the food in the water. A strong correlation between gill racker morphology and fish status (Canan *et al.*, 2012; Kumari *et al.*, 2014). There exist a coefficient of correlation between the sequence of gill rakers and space between them and the feeding habit shown by the fish. In the present study, the fish show the presence of four-gill arches provided by racks that help hold part of the food. Centrobranchial indicates the presence of 6 pharyngeal teeth that help break down imported food (Kumari *et al.*, 2014; Dey *et al.*, 2015; Pise *et al.*, 2018). Oesophagus performs the function of transferring food from the buccal cavity to the stomach (Abdulhadi, 2005; Nazlić *et al.*, 2014; Boćina *et al.*, 2017). fish. Digestion occurs in the stomach (Diaz *et al.*, 2003, Pise *et al.*, 2018). The intestines are a composite structure divided by the anterior and posterior regions, the observations of *Osteobrama vigorsii* (Sykes, 1839) show similar observations in a study by (Abdulhadi, 2005; Diaz *et al.*, 2008; Boćina *et al.*, 2017). The intestines keep the rectum open outside with the anus. Current work will help to understand the digestive tract, food utilization, and nutrient uptake of fish that make them good sources of protein and minerals. This study will focus on the science of fishing to develop a sustainable conservation management system.

CONCLUSION

The present study on *Osteobrama vigorsii* (Sykes, 1839) from Nira River, can help the fishery unit, to plan strategies for the conservation of the endemic fish in their natural habitat. The availability of food resources can be planned thereby providing a continuous source of food to the fish in its natural habitat. Since the availability of food is directly related to the reproductive potential of the fish.

ACKNOWLEDGMENTS: I would like to express my gratitude towards M.E.S. Abasaheb Garware College, as well as the research center of Modern College of Arts Commerce and Science Ganeshkhind. Pune-1. for their kind support during the study period.

CONFLICT OF INTEREST: None

FINANCIAL SUPPORT: None

ETHICS STATEMENT: None

REFERENCES

- Abaurrea-Equisoain, M. A., & Ostos-Garrido, M. V. (1996). Enterocytes in the anterior intestine of *Oncorhynchus mykiss*: Cytological characteristics related to osmoregulation. *Aquaculture*, 139(1-2), 109-116.
- Abdulhadi, H. A. (2005). Some comparative histological studies on alimentary tract of tilapia fish (*Tilapia spilurus*) and sea bream (*Mylio cuvieri*). *Egyptian Journal of Aquatic Research*, 31(1), 387-398.
- Agarwal, N. K. (1996). *Fish Reproduction*, APH Publishing Corporation, New Delhi, 264.
- Agbugui, M. O., & Oniye, S. J. (2019). Aspects of the Biology of *Protopterus annectens* from Agenebode at River Niger, Nigeria. *Egyptian Journal of Aquatic Biology and Fisheries*, 23(1), 37-45.
- Alabssawy, A. N., Khalaf-Allah, H. M., & Gafar, A. A. (2019). Anatomical and histological adaptations of digestive tract in relation to food and feeding habits of lizardfish, *Synodus variegatus* (Lacepède, 1803). *The Egyptian Journal of Aquatic Research*, 45(2), 159-165.
- Al-Awady, A. A. M. (2013). Food habits of common carp (*Cyprinus carpio* L., 1758) in Main Outfall Drain, Al-Nassiriya, Iraq. *University of Thi-Qar Journal of Science*, 3(4), 9-17.
- Albrecht, M. P., Ferreira, M. F. N., & Caramaschi, E. P. (2001). Anatomical features and histology of the digestive tract of two related neotropical omnivorous fishes (Characiformes; Anostomidae). *Journal of Fish Biology*, 58(2), 419-430.
- Boćina, I., Šantić, Ž., Restović, I., & Topić, S. (2017). Histology of the digestive system of the garfish *Belone belone* (Teleostei: Belonidae). *The European Zoological Journal*, 84(1), 89-95.
- Canan, B., Nascimento, W. S. D., Siliva, N. B. D., & Chellappa, S. (2012). Morphohistology of digestive tract of damselfish *Stegastes fuscus* (Osteichthyes: Pomacentridae). *The Scientific World Journal*, 2012, 1-9.
- de Melo Germano, R., Stabile, S. R., de Britto Mari, R., Pereira, J. N. B., Faglioni, J. R. S., & de Miranda Neto, M. H. (2014). Morphological characteristics of the *P. terodoras granulatus* digestive tube (V alenciennes, 1821)(Osteichthyes, D oradidae). *Acta Zoologica*, 95(2), 166-175. doi:10.1111/azo.12016.
- Dey, S., Misra, K. K., & Homechoudhuri, S. (2015). Distribution of gustatory system in the lips of spotted snakehead, *Channa punctatus* (Bloch 1793) and spiny eel, *Mastacembelus pancalus* (Hamilton 1822) from India. *World Journal of Fish and Marine Sciences*, 7(4), 247-262.
- Díaz, A. O., García, A. M., & Goldemberg, A. L. (2003). Glycoconjugates in the mucosa of the digestive tract of *Cynoscion guatucupa*: a histochemical study. *Acta Histochemica*, 110(1), 76-85.
- El-Naggar, H. A., Allah, H. M. K., Masood, M. F., Shaban, W. M., & Bashar, M. A. (2019). Food and feeding habits of some Nile River fish and their relationship to the availability of natural food resources. *The Egyptian Journal of Aquatic Research*, 45(3), 273-280.

- Garcia, S. M., Kolding, J., Rice, J., Rochet, M. J., Zhou, S., Arimoto, T., Beyer, J. E., Borges, L., Bundy, A., Dunn, D., et al. (2012). Reconsidering the consequences of selective fisheries. *Science*, 335(6072), 1045-1047.
- German, D. P., Gawlicka, A. K., & Horn, M. H. (2014). Evolution of ontogenetic dietary shifts and associated gut features in prickleback fishes (Teleostei: Stichaeidae). *Comparative Biochemistry and Physiology Part B: Biochemistry and Molecular Biology*, 168, 12-18.
- German, D. P., Nagle, B. C., Villeda, J. M., Ruiz, A. M., Thomson, A. W., Contreras Balderas, S., & Evans, D. H. (2010). Evolution of herbivory in a carnivorous clade of minnows (Teleostei: Cyprinidae): effects on gut size and digestive physiology. *Physiological and Biochemical Zoology*, 83(1), 1-18.
- Hossain, M. I., Nipa, F. R., Tumpa, A. S., Mannan, M. A., & Bhuyain, M. A. B. (2010). Food and feeding habit of Puntius sarana in the river of Padma, Rajshahi, Bangladesh. *Trends in Fisheries Research*, 1(3), 2319-4758.
- Joadder, A. R., & Hossain, M. D. (2008). Observation on the food and feeding habit of *Cyprinus carpio* var. *communis* (Linnaeus)(Cypriniformes: Cyprinidae). *Journal of Science Foundation*, 6(2), 95-99.
- Joadder, M. R. (2006). Food and feeding habits of *Gagata youssoufi* (Rahman) from the river Padma in Rajshahi. *University Journal of Zoology, Rajshahi University*, 25, 69-71.
- Khaing, M. M., & Khaing, K. Y. M. (2020). Food and feeding habits of some freshwater fishes from ayeyarwady river, mandalay district, Myanmar. In *IOP Conference Series: Earth and Environmental Science*, 416(1), 012005. doi:10.1088/1755-1315/416/1/012005.
- Kumari, U., Mittal, S., & Mittal, A. K. (2014). Histological and histochemical investigations of the pharyngeal jaw apparatus of a carp *Cirrhinus mrigala*. *Acta Histochemica*, 116(3), 421-434.
- Løkka, G., Austbø, L., Falk, K., Bjerkås, I., & Koppang, E. O. (2013). Intestinal morphology of the wild Atlantic salmon (*Salmo salar*). *Journal of Morphology*, 274(8), 859-876.
- Lawson, E. O., & Aguda, A. F. (2010). Growth patterns, diet composition and reproduction in the ten pounder, *Elops lacerta* from Ologe lagoon, Lagos, Nigeria. *Agriculture and Biology Journal of North America*, 1(5), 974-984.
- Manoharan, J., Gopalakrishnan, A., Varadharajan, D., Thilagavathi, B., & Priyadharsini, S. (2012). Stomach content analysis of *Terapon jarbua* (Forsskal) from Parangipettai coast, South East Coast of India. *Advances in Applied Science Research*, 3(5), 2605-2621.
- Manon, M. R., & Hossain, M. D. (2011). Food and feeding habit of *Cyprinus carpio* var. *specularis*. *Journal of Science Foundation*, 9(1-2), 163-169.
- Murray, H. M., Wright, G. M., & Goff, G. P. (1996). A comparative histological and histochemical study of the post-gastric alimentary canal from three species of pleuronectid, the Atlantic halibut, the yellowtail flounder and the winter flounder. *Journal of Fish Biology*, 48(2), 187-206.
- Nazlić, M., Paladin, A., & Bočina, I. (2014). Histology of the digestive system of the black scorpionfish *Scorpaena porcus* L. *Acta Adriatica*, 55(1), 65-74.
- Pise, M., Gorule, P. A., Kharat, S., Tapkir, S. D., Verma, C., Kumkar, P., & Gosavi, S. M. (2018). Length-weight relationships of four freshwater fishes from northern Western Ghats of India. *Journal of Applied Ichthyology*, 34(6), 1394-1396.
- Potthoff, T., Kelley, S., Moe, M., & Young, F. (1984). Description of porkfish larvae (*Anisotremus virginicus*, Haemulidae) and Skeletal ontogeny in greater amberjack 315 their osteological development. *Bulletin of Marine Science*, 34(1), 21-59.
- Purushothaman, K., Lau, D., Sajju, J. M., Sk, S. M., Lunny, D. P., Vij, S., & Orbán, L. (2016). Morpho-histological characterisation of the alimentary canal of an important food fish, Asian seabass (*Lates calcarifer*). *PeerJ*, 4, e2377.
- Rodrigues, S. S., Navarro, R. D., & Menin, E. (2006). Anatomia do tubo digestório de *Leporinus macrocephalus* Garavello & Britski, 1988 (Characiformes, Anostomidae) em relação ao seu hábita alimentar. *Journal of Biosciences.(Online)*, 86-95.
- Santos, M. L. D., Arantes, F. P., Pessali, T. C., & Santos, J. E. D. (2015). Morphological, histological and histochemical analysis of the digestive tract of *Trachelyopterus striatulus* (Siluriformes: Auchenipteridae). *Zoologia (Curitiba)*, 32, 296-305.
- Shukla, S. N., & Patel, V. (2013). Studies on food and feeding behaviour of *Cyprinus carpio* and their gastrosomatic index from Govindgarh Lake, Rewa (MP), India. *Online International Interdisciplinary Research Journal*, 3, 116-122.
- Wilson, J. M., & Castro, L. F. C. (2010). Morphological diversity of the gastrointestinal tract in fishes. In: Grossell M, Farrell AP, Brauner CJ. *The multifunctional gut of fish*. New York: Academic Press, p. 2-44.
- Xiong, D., Zhang, L., Yu, H., Xie, C., Kong, Y., Zeng, Y., Huo, B., & Liu, Z. (2011). A study of morphology and histology of the alimentary tract of *Glyptosternum maculatum* (Sisoridae, Siluriformes). *Acta Zoologica*, 92(2), 161-169.
- Yashpal, M., Kumari, U., Mittal, S., & Mittal, A. K. (2009). Morphological specializations of the buccal cavity in relation to the food and feeding habit of a carp *Cirrhinus mrigala*: a scanning electron microscopic investigation. *Journal of Morphology*, 270(6), 714-728.